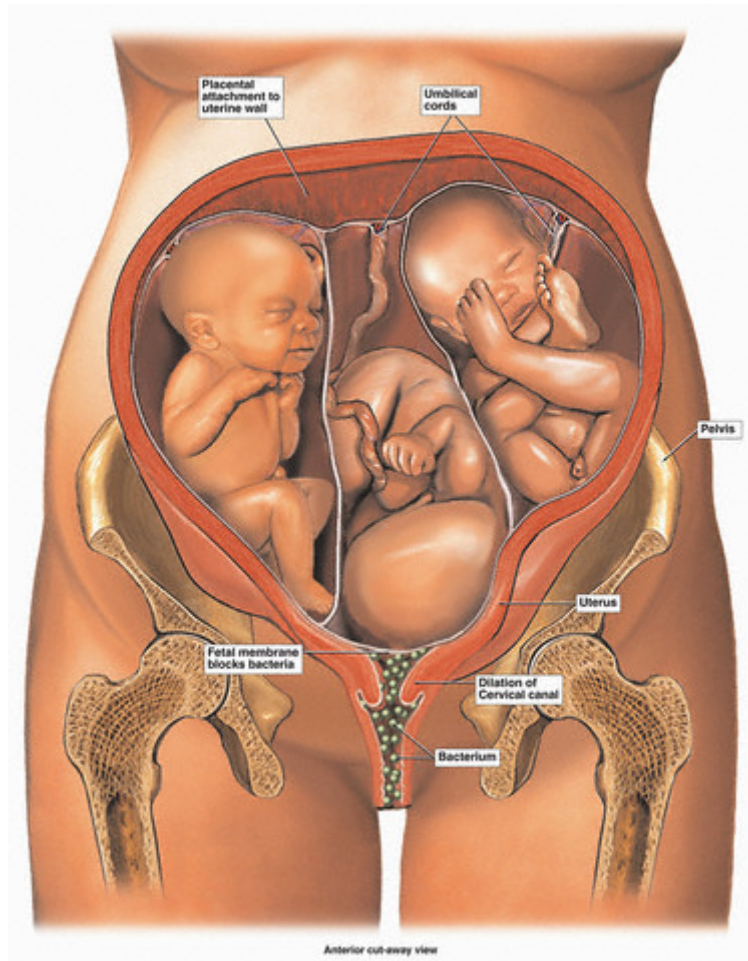
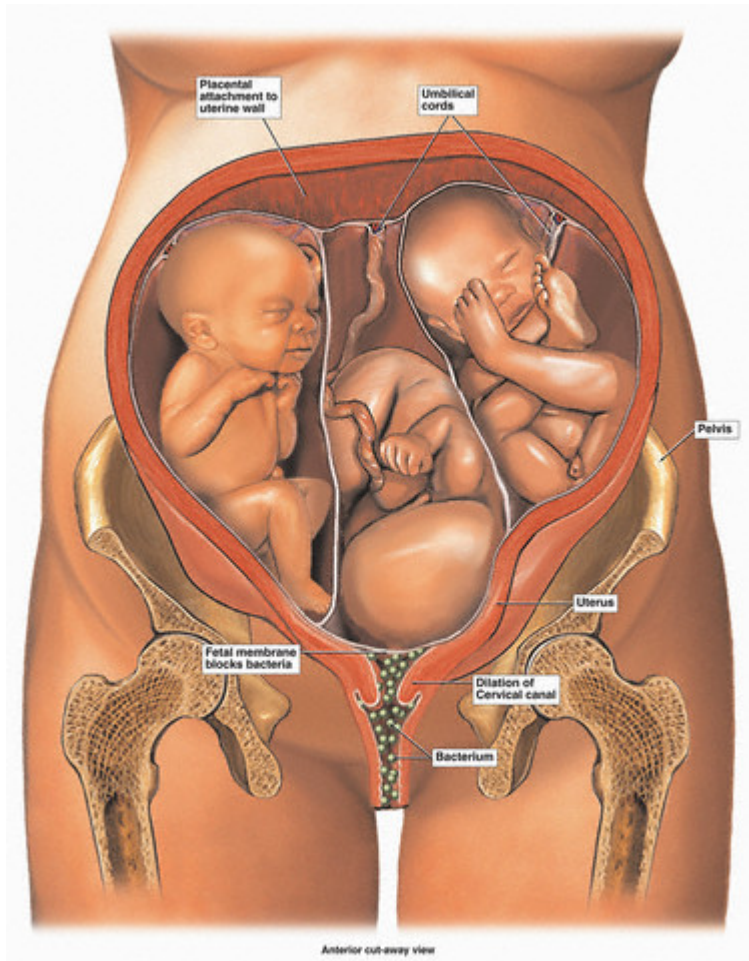


Twenty-Four Week Old Triplets In-Utero





This medical exhibit pictures three twenty-four (24) week old triplets in utero from an anterior (front) cut-away view. Also illustrated are the fetal membranes surrounding each baby, as well as the mother's uterus, cervix and vagina (birth canal). The medical illustration also depicts the early dilation of the mother's cervix and the blocking mechanism of the fetal membranes preventing bacteria from contacting the fetuses. — Image by © Visuals Unlimited/Corbis